

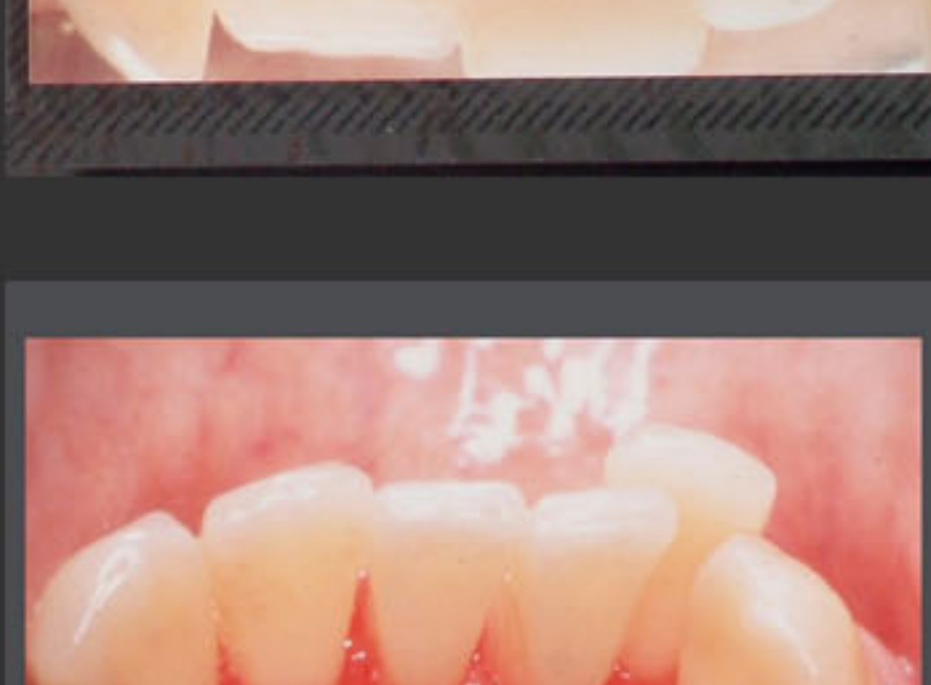### Interdisciplinary Treatment plan:

- Oral hygiene instruction
- Supportive periodontal Tx (scaling, root planing)
- Preparatory Phase (capping, endo, post and core, temporary crowns)
- Evaluation of plaque control
- Extraction of lower left incisor for (1) poorest perio. condition, (2) not to flare lower incisors, (3) shorter treatment time, (4) easier to clean
- Bonding of fixed orthodontic appliance
- Leveling and alignment
- Closure of residual space, adjustment of upper temporary crown width
- Surgical phase of periodontal tx ( open curettage, alveoplasty) for posterior teeth
- Detailing and finishing of tooth position
- Debonding of fixed orthodontic appliance
- Delivery of upper wraparound and lower 3-3 bonded retainers
- Retention follow up
- Re-evaluation of provisional treatment results
- Final restorations and prostheses
- Maintenance

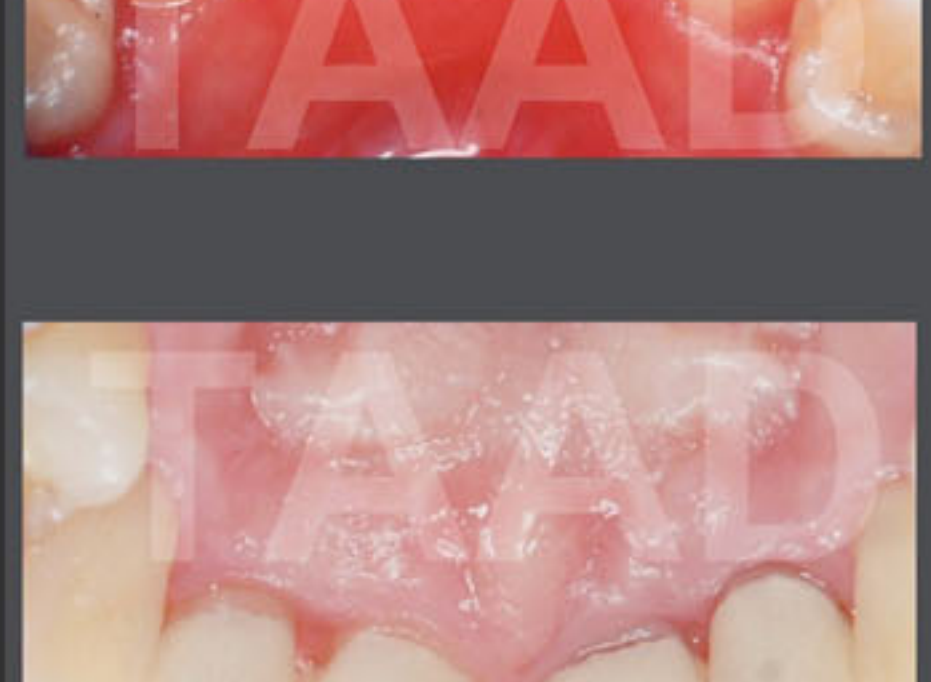### Summary of Treatment Flow:

- Oct. ~ , 1995 Initial visit, records, consultation
- Nov., 1995 ~ Jan., 1996 Supportive periodontal and preparatory dental treatment
- Feb. ~ , 1996 Extraction of # 31, bonding of orthod. Appliance
- Apr. ~ , 1996 Plaque Control (every 3 months)
- Sep. , 1996 Surgical phase of periodontal tx
- Mar. ~ , 1997 Debonding of orthodontic appliance
- Mar. ~ Sep., 1997 Orthodontic retention
- Oct., 1997 ~ Mar., 1998 Re-evaluation of provisional results
- Apr. , 1998 Final restorations and prostheses
- May ~ , 1998 Follow up periodically

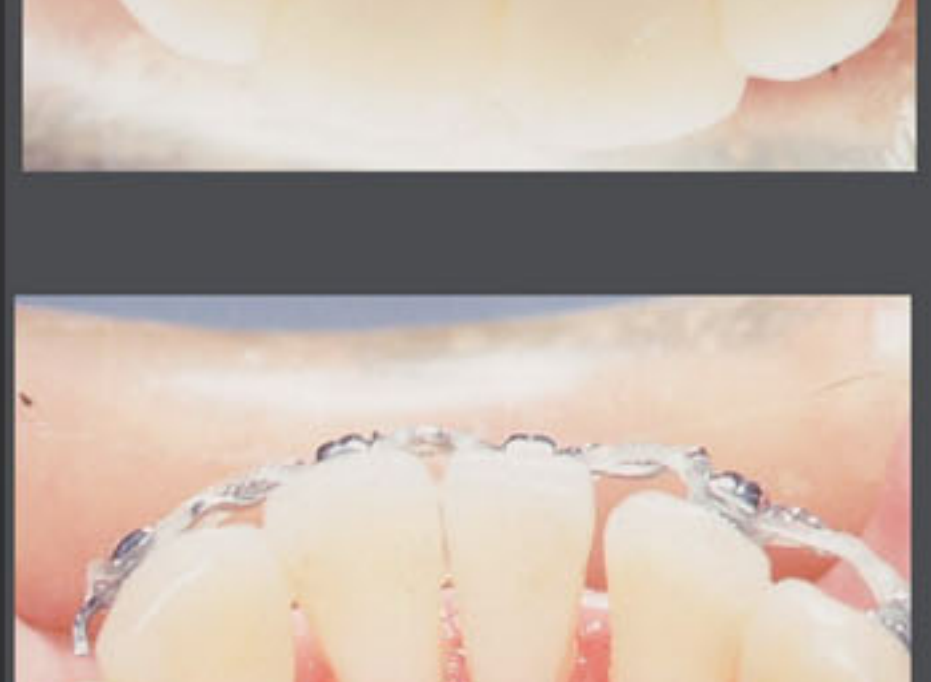
### ◆ Plaque Control Records



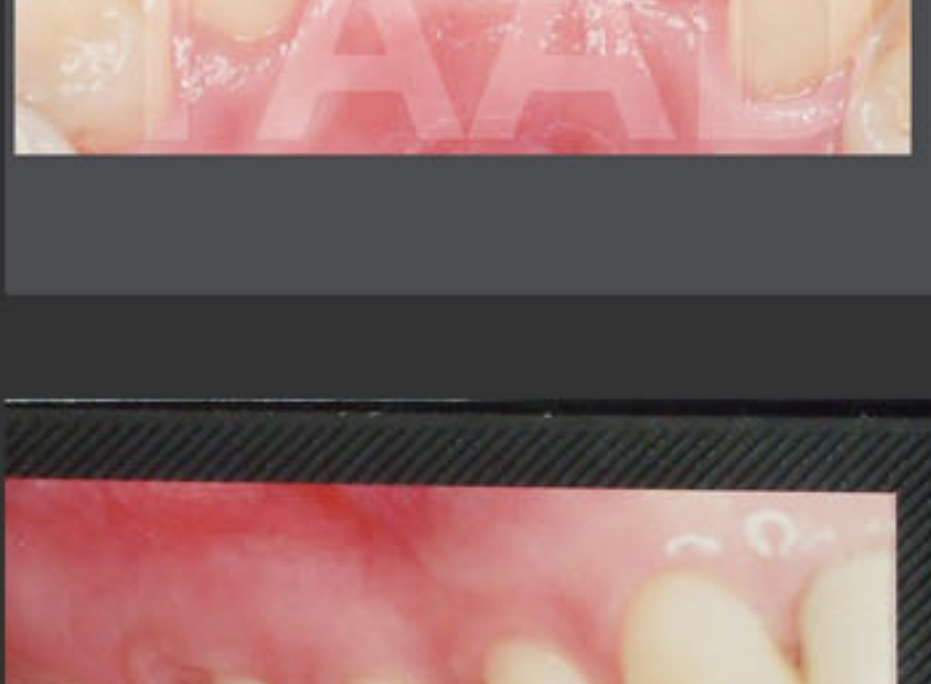
Post- Scaling and Root Planing, Frontal View



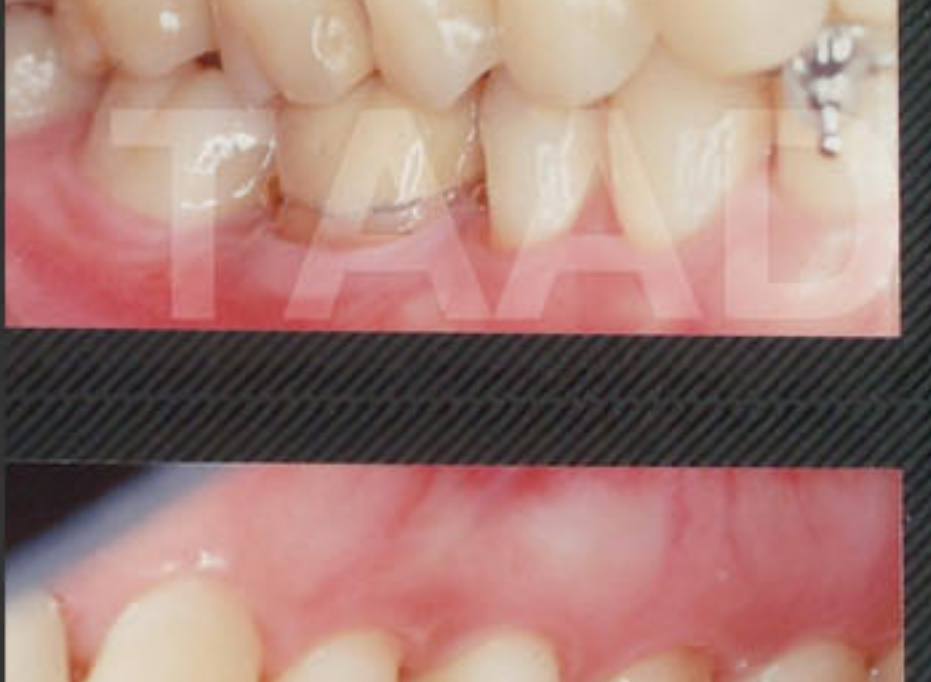Upper Incisors, Occlusal View



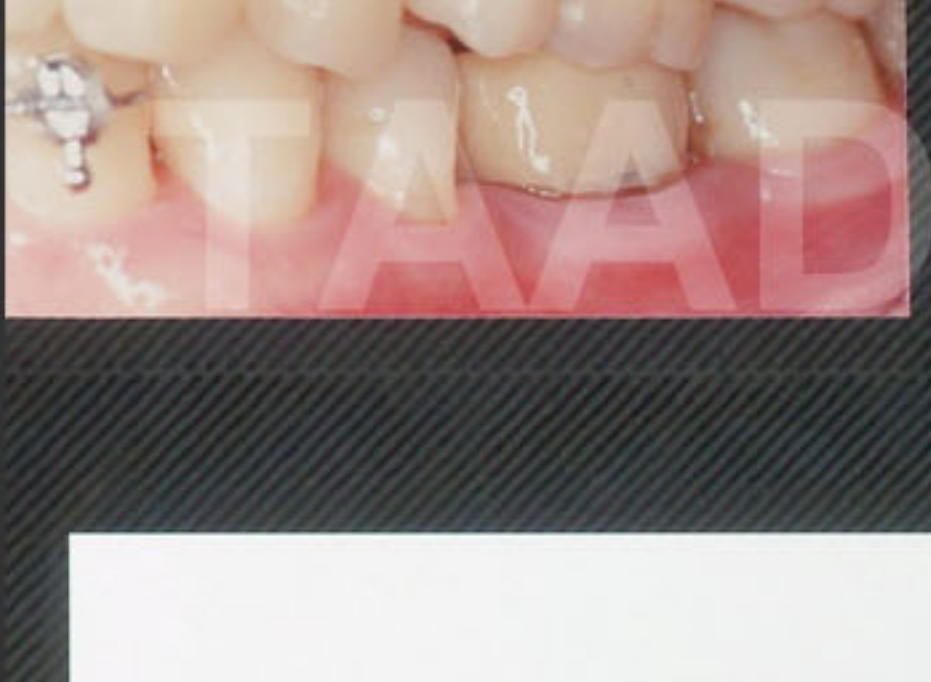Lower Incisors, Occlusal View



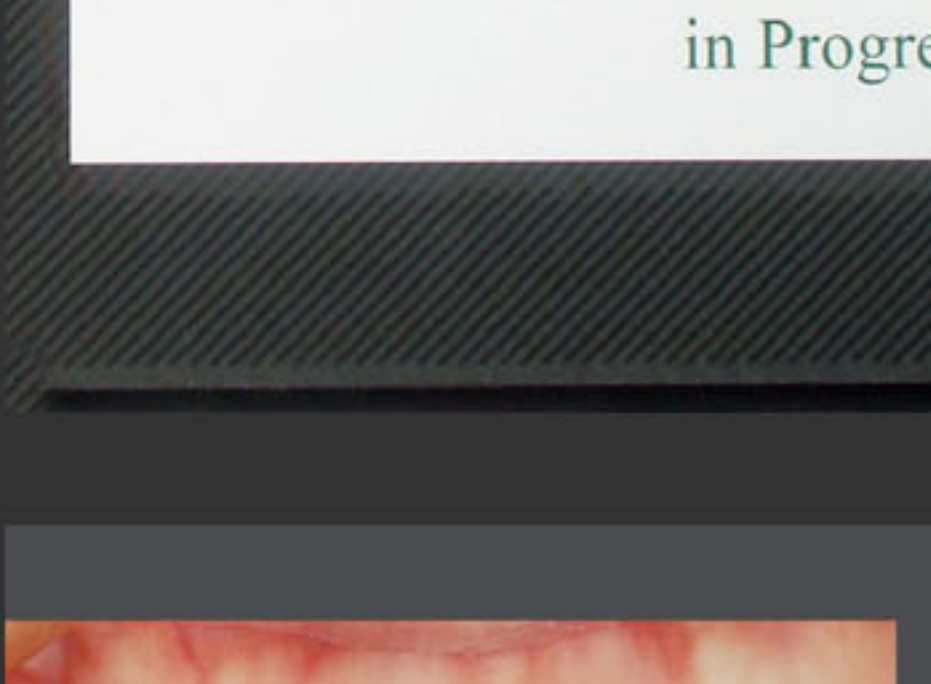
Plaque Control during Orthodontic Treatment Upper Incisors, Occlusal View



Plaque Control during Orthodontic Treatment Lower Incisors, Occlusal View



Post-Periodontal Surgery Right Lateral View




Post-Periodontal Surgery Left Lateral View

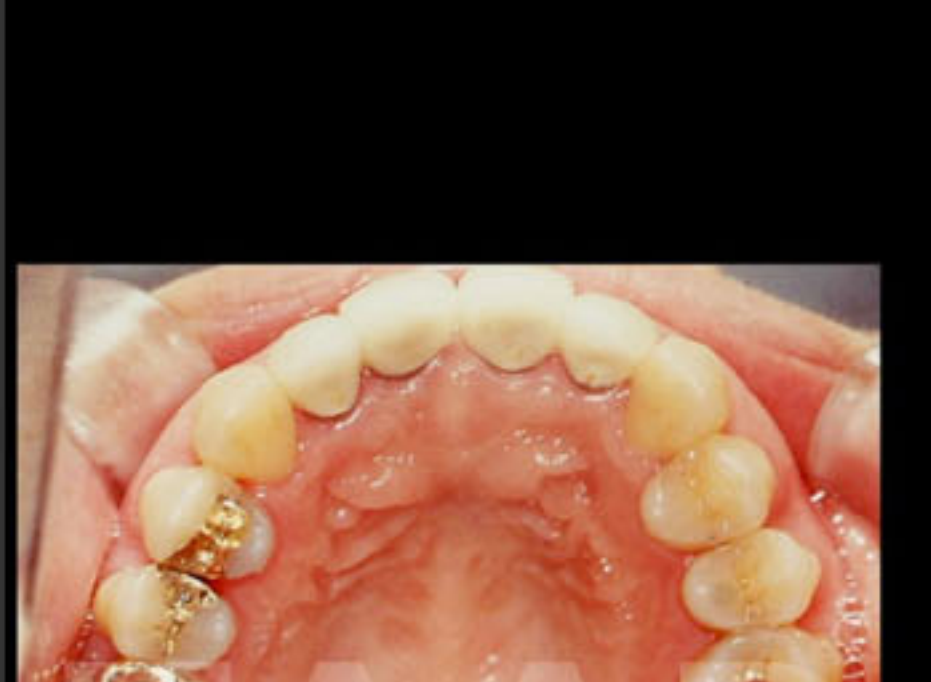### ◆ Orthodontic Treatment in Progress



Upper Teeth Aligned, Lower Space Closed, Frontal View



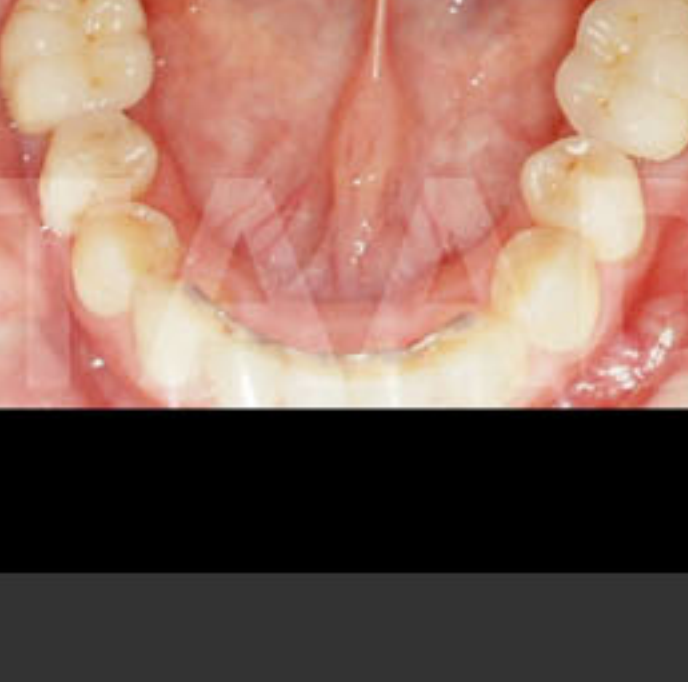Upper Braces Removed, Lower Incisors Finishing Frontal View



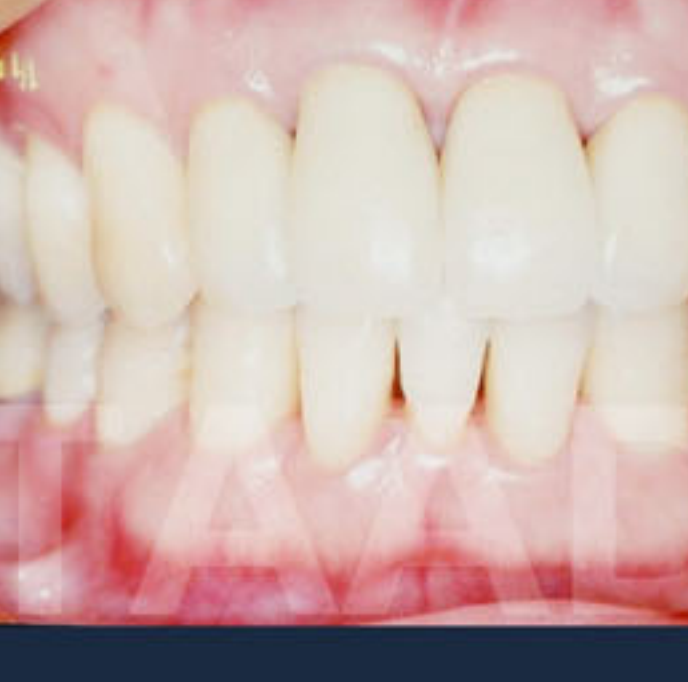Paralleling of Lower Incisor Roots, Frontal Closed-up View

### ◆ Post- treatment Records

*Facial photos*



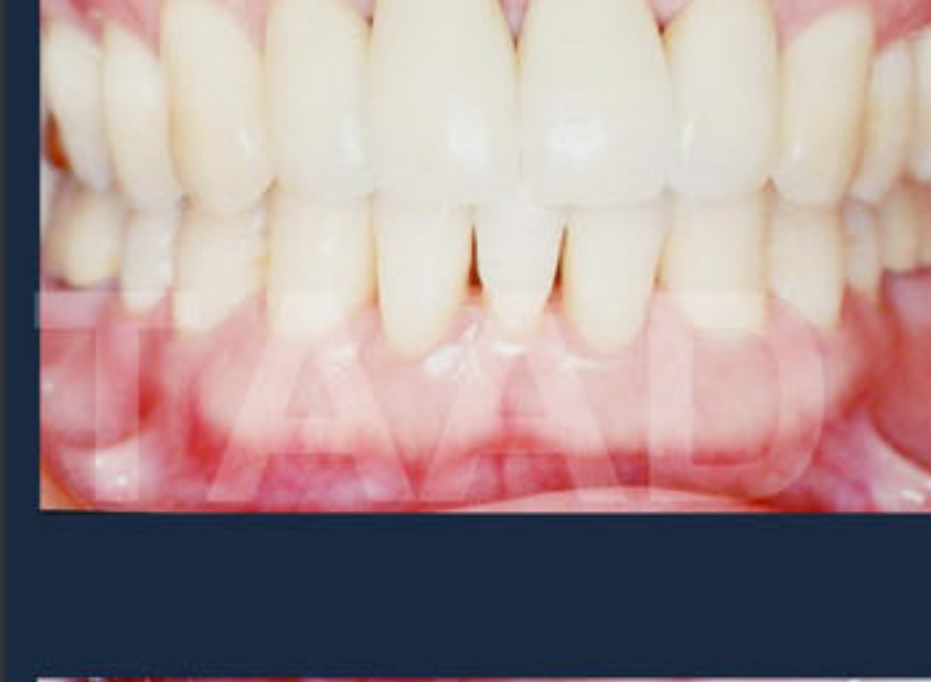Smile View



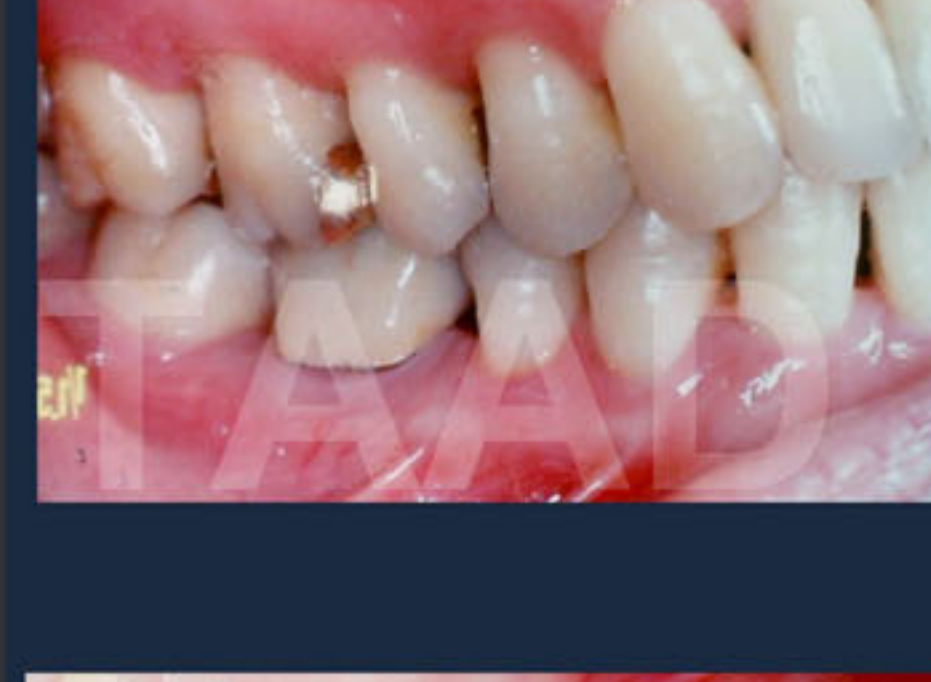Lateral View

### ◆ Post- treatment Records

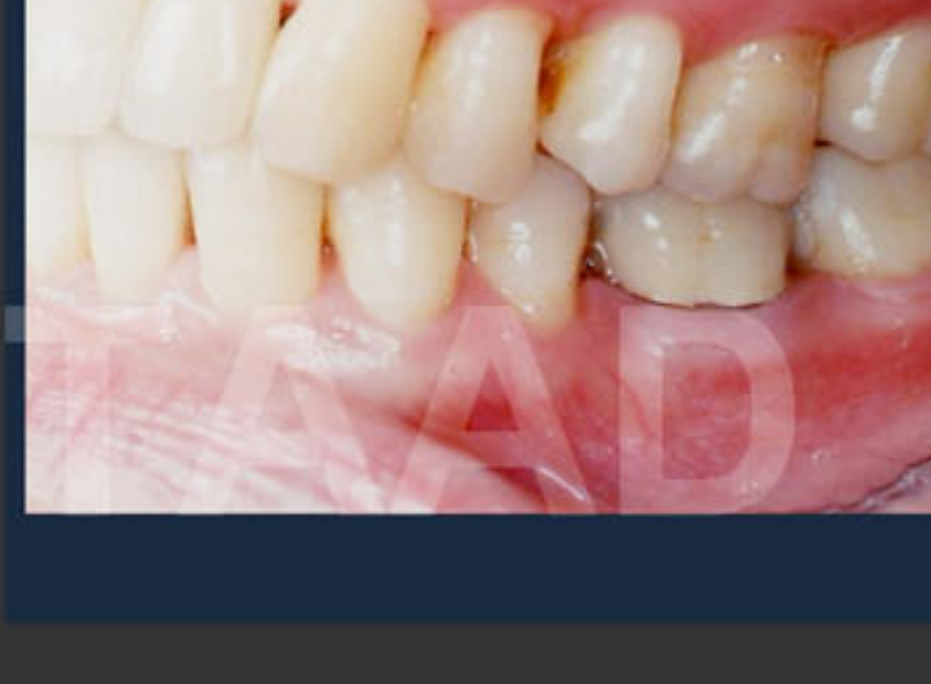*Intra-oral photos*



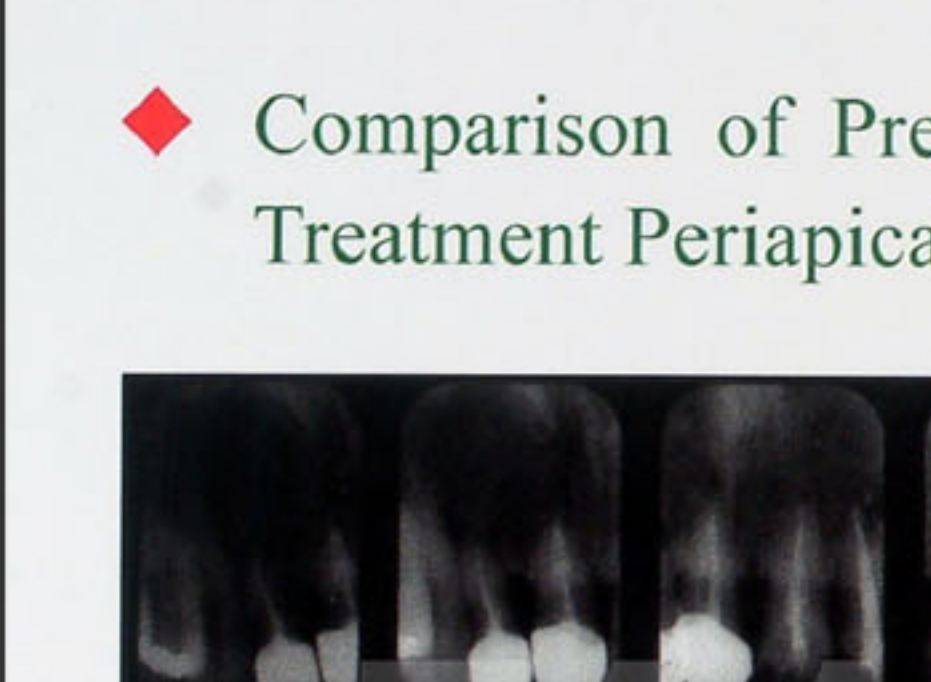
Upper Occlusal View



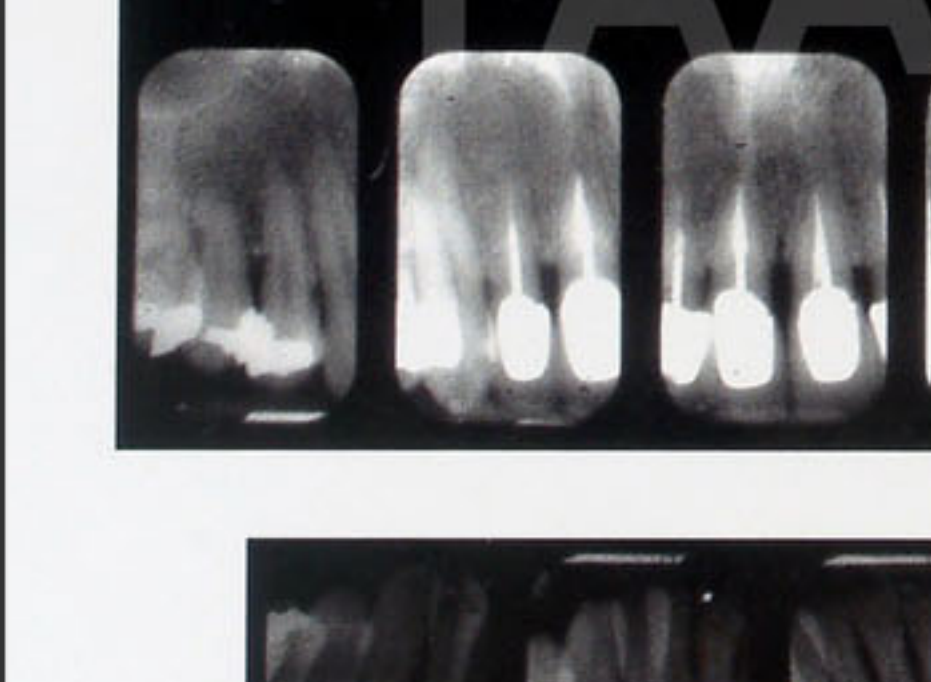
Lower Occlusal View



Frontal View



Right Lateral View



Left Lateral View

### ◆ Comparison of Pre- and Post-Treatment Periapical X-ray

